



PATIENT

Paris Feitshans

SPECIES

Canine

BREED

Terrier Mix

SEX

FS

AGE

10 y

WEIGHT

11.3 lb

INTERPRETED BY

Keith Blass, DVM, MS,
DACVIM (Cardiology)

IMAGING PERFORMED BY

Brandi Kurzowski

HOSPITAL NAME

Corfu VC

REFERRING VET

Dr. Beatty

INVOICE

DATE

11/11/25

PRESENTING CLINICAL SIGNS

Grade 2/6 left-sided murmur. Previously diagnosed with degenerative valve disease. Not receiving any cardiac therapy.

ECHOCARDIOGRAPHIC FINDINGS

2D, M-mode, and Doppler study.

Left atrial size is normal. The mitral valve leaflets are mildly thickened and exhibit systolic prolapse. There is Doppler evidence of mitral regurgitation present. Left ventricular dimensions are normal. Left ventricular systolic function is normal. The aorta and aortic valve are normal. Right atrial and right ventricular dimensions are normal. The tricuspid valve leaflets are mildly thickened, and there is Doppler evidence of tricuspid regurgitation present. TR velocity does not suggest the presence of pulmonary hypertension. The pulmonary artery and pulmonic valve are normal. No shunting lesions are visualized. No pericardial effusion or cardiac masses are seen.

LA - 21.2 mm
LVIDd - 21.9 mm
LVIDs - 13.4 mm
FS - 38.8%
RA - 16.8 mm
LVOT - 1.08 m/s
RVOT - 0.82 m/s

ASSESSMENT/RECOMMENDATIONS

Degenerative mitral and tricuspid valve disease - stage B1

This examination demonstrates regurgitation of blood across Paris's mitral and tricuspid valves resulting from her previously diagnosed degenerative valve disease. The hemodynamic effects of the regurgitations appear to be mild, as Paris does not have secondary dilation of any of her cardiac chambers, and her ventricular systolic function is normal. As such, Paris's current risk for the development of clinical signs secondary to her valvular diseases, such as coughing, exercise intolerance, syncope, labored breathing, and abdominal distension, appears to be low.

No therapy is recommended at this stage of Paris's valvular diseases.

A recheck echocardiogram is recommended in 6-9 months to monitor for disease progression.



PATIENT

Paris Feitshans

SPECIES

Canine

BREED

Terrier Mix

SEX

FS

AGE

10 y

WEIGHT

11.3 lb

INTERPRETED BY

Keith Blass, DVM, MS,
DACVIM (Cardiology)

IMAGING PERFORMED BY

Brandi Kurzowski

HOSPITAL NAME

Corfu VC

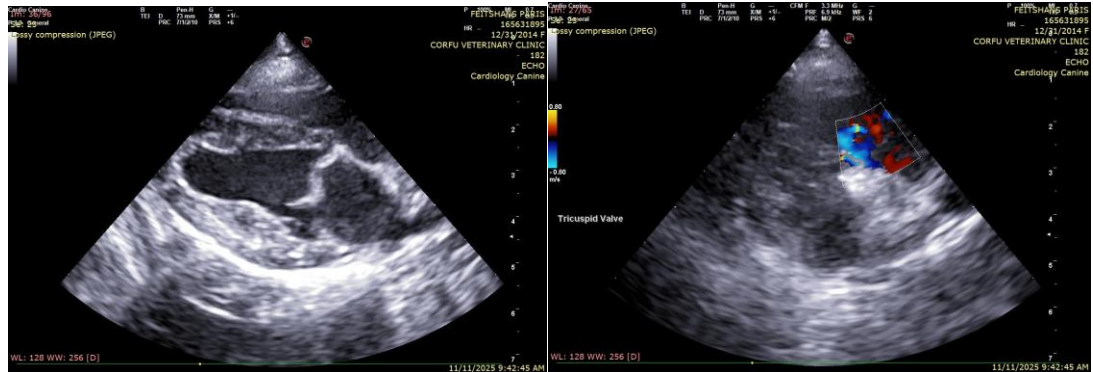
REFERRING VET

Dr. Beatty

INVOICE

DATE

11/11/25



The information and recommendations provided are based on the images presented by the referring veterinarian/sonographer. No evaluation can be communicated regarding pathology that was not visible in the image/video clips provided.

Thank you for this referral. If the clinical or image interpretation does not parallel your findings or if I can be of any further assistance please contact me.

Keith Blass, DVM, MS, DACVIM (Cardiology)

info@SonoPath.com